



Review Article

Ommaya Reservoir Related Complications: A Single Center Experience and Review of Current Literature

Azka Ali¹, Raphael Charles Bosse¹, Bently Patrick Doonan¹, Preeti Narayan², Grant Alan Jester¹, Jess David Delaune¹, Jacob Leo Barish¹, Samantha Leigh Welniak¹, Hannah Friggle Norton³, Coy Don Heldermon^{2,*}

¹Department of Internal Medicine, University of Florida, Gainesville, USA

²Division of Hematology and Oncology, University of Florida, Gainesville, USA

³Health Science Center Libraries, University of Florida, Gainesville, USA

Email address:

coy.heldermon@medicine.ufl.edu (C. D. Heldermon)

*Corresponding author

To cite this article:

Azka Ali, Raphael Charles Bosse, Bently Patrick Doonan, Preeti Narayan, Grant Alan Jester, Jess David Delaune, Jacob Leo Barish, Samantha Leigh Welniak, Hannah Friggle Norton, Coy Don Heldermon. Ommaya Reservoir Related Complications: A Single Center Experience and Review of Current Literature. *International Journal of Clinical Oncology and Cancer Research*. Vol. 4, No. 2, 2019, pp. 10-24.

doi: 10.11648/j.ijcoocr.20190402.12

Received: February 21, 2019; **Accepted:** April 8, 2019; **Published:** June 11, 2019

Abstract: First introduced in 1963, ommaya reservoirs (OmRs) are indwelling intraventricular catheters used for decompression of hydrocephalus, antibiotics, and chemotherapy delivery. They are important alternatives when lumbar punctures are not practical or when long-term administration of medications is needed. Despite being used for over 50 years, placement of these devices can still contribute to significant morbidity and mortality. We performed a single-center retrospective review at the University of Florida Cancer Center evaluating OmR related complications in patients in whom OmR was placed for chemotherapy. We also conducted a systematic review of OmR related and LP complications in setting of chemotherapy delivery. 13 patients met criteria for inclusion in this retrospective study. Time points evaluated for complications were: placement, up to 6 months, 6-12 months, > 12 months, removal and post-discharge. Our institutional data showed a complicated rate of <7% at each time point. For systematic review, 38 studies were reviewed for OmR data, and 8 studies were reviewed for LP data. Infectious complications were more prevalent in OmR studies with statistical significance ($p=0.0017$), whereas noninfectious complications were more prevalent in LP studies with statistical significance ($p=0.0004$). This study compared complication rates from infectious and non-infectious sources between patients receiving intrathecal chemotherapy through Ommaya reservoirs versus lumbar puncture. OmR can be very useful in long-term administration of medication, and the relatively high complication rate (especially infectious) can be deemed an acceptable risk for patient population with high morbidity.

Keywords: Ommaya Reservoir, Lumbar Puncture, Chemotherapy

1. Introduction

Ommaya reservoirs (OmRs) are intracranial indwelling catheters placed to temporarily relieve obstruction from compressive hydrocephalus and for the delivery of medications beyond the blood brain barrier. [1-3] They were first introduced in 1963 by Dr. Ommaya for administration of

intraventricular medications such as antibiotics, and have since become the mainstay for chemotherapy delivery and offer a painless, easily accessible alternative to serial lumbar punctures (LPs). [3] The OmR is a dome-shaped device with a catheter attached to its base which is inserted into the ventricle. A burr-hole is made into the skull through which the catheter is inserted. The dome rests between the skull and the scalp, and provides an easy access for repetitive drug administration.

It is made from a self-sealing material and can be accessed up to 200 times before encountering a leak. [1, 4] Intrathecal chemotherapy enables heavy molecular weight chemotherapeutics to bypass the blood-brain barrier and ensures adequate drug delivery to the CNS. Although repeated lumbar punctures provide easy access to cerebrospinal fluid (CSF), multiple studies have shown repeated access can cause fibrosis in the subarachnoid space, as well as inconsistent drug levels. [5]

Despite the ease of access and improved delivery of therapy to the active sites of disease, complications associated with their placement and function and the stigma of brain surgery has limited widespread OmR use. In a thorough review, Cohen-Pfeffer et al discuss OmR-related complications in patients receiving OmR for both oncologic and non-oncologic indications. [6] Their study, among others, reported that the major complications of OmR placement include technical malfunction during placement, catheter malposition and migration, intracerebral hemorrhage, reservoir exposure, seizures, and central nervous system infections.[2] Overall, serious complications are infrequent and the most common complications are infections.[7] Though rare, infectious complications have seen an uptick in frequency, in part due to increased use of antibiotics for primary prophylaxis in patients with hematologic malignancies, the most frequent recipients of OmR. [8, 9] To counter this, several hospital systems have adopted infection-control bundle measures for OmR placement which have cut down on infection rates.[10] Complications arising from technical placement and manipulation of OmR continue to decline as a result of the development of more sophisticated approaches to placement such as the stealth-guided neuro-navigational approach and through increased familiarity of placement by neurosurgeons. [5]

Though beneficial and relatively easy to place in most individuals, there are circumstances where OmR placement is too hazardous or contraindicated. These include cases: an infection risk higher than average based on systemic or neurologic symptoms and/or the presence of known active infection; and patients with aggressive disease with a poor predicted response to intrathecal (IT) chemotherapy. Performance status of the patient is also paramount for consideration while assessing for benefits of OmR placement.[11] In the present study, our group sought to determine the complication rate of OmR placement at the University of Florida Cancer Center in Gainesville, FL, and determine their utility in cancer patients. In addition, given the paucity of literature on this subject, a systematic review of the available literature on OmR complications and lumbar puncture related-complications for intrathecal chemotherapy was performed and described. We compared the complication outcomes between the two modes of chemotherapy delivery in the systematic review to assess if complication rates with either intervention is prohibitive or outweighs benefits.

2. Patients and Methods

We conducted a single-center retrospective review of

patients who had an OmR placed at the University of Florida Cancer between January 2011 and December 2016. This study protocol was approved by University of Florida Institutional Review Board (IRB), and all research was performed according to the guidelines and regulations of the IRB. The IRB approval also served as a waiver of individual patient informed consent. This time period was selected because 2011 was the year of implementation of the electronic medical record (EMR) at our institution which facilitated accurate data extraction. Inclusion criteria in the study group included OmR placed at UF for any indication. Subgroup analysis was performed specifically on those patients receiving OmR for administration of IT chemotherapy. Both adult and pediatric patients were included in the study and all cancer types were included. Exclusion criteria included patients who had OmR placed outside of UF, even if they were treated for OmR complications at UF, to ensure surgical placement of OmR was maintained at a single center.

UF Integrated Data Repository (IDR) assisted in extracting patient charts by screening for ICD-9/ICD-10 codes for cancer diagnoses and OmR placement. All charts were then individually reviewed and patients who did not meet above inclusion or those that met exclusion criteria were omitted from the study. Patient demographics, cancer specific data, and OmR data was then collected on all patients. Study data were collected and managed using REDCap (Research Electronic Data Capture) electronic data capture tools hosted at the University of Florida.[12] REDCap is a secure, web-based application designed to support data capture for research studies, providing 1) an intuitive interface for validated data entry; 2) audit trails for tracking data manipulation and export procedures; 3) automated export procedures for seamless data downloads to common statistical packages; and 4) procedures for importing data from external sources.

The present study also encompasses a systematic review of current literature to study OmR complications and comparing OmR versus lumbar puncture complications. Studies were selected from first placement of OmRs in the 1960s to current literature including studies published in year 2018. Inclusion criteria included placement of OmR for intrathecal chemotherapy delivery, and sequential lumbar punctures for intrathecal chemotherapy delivery. Pediatric and adult patients were included. Exclusion criteria included studies with patients with OmR for another indication besides chemotherapy.

We performed a systematic review of the medical literature on the complications arising from Ommaya reservoirs and/or lumbar punctures used for administering chemotherapy (Figure 1). Databases searched included PubMed/MEDLINE, Web of Science, Cochrane CENTRAL Register of Controlled Trials, and ClinicalTrials.gov. In each database, we searched on variations of terms related to Ommaya reservoirs, lumbar puncture, chemotherapy, and complications. Searches in PubMed and Cochrane CENTRAL included medical subject headings. No date restriction was placed on the search results; language was limited to English. Meeting abstracts were

reviewed but not included in the final data review. Full search strategies are available in Appendix 1. Exclusion criteria included studies discussing OmR placement for indications other than chemotherapy delivery, studies focusing on OmR placement techniques as primary outcome instead of infectious complications, and studies discussing lumbar punctures done for indications other than chemotherapy

delivery. Inclusion criteria included studies with adult and pediatric patients in whom OmR was placed for the delivery of IT chemotherapy, and studies reporting infectious and non-infectious complications as a result of OmR placement or LPs in the setting of IT chemotherapy delivery. Time span of studies included 1968-2018.

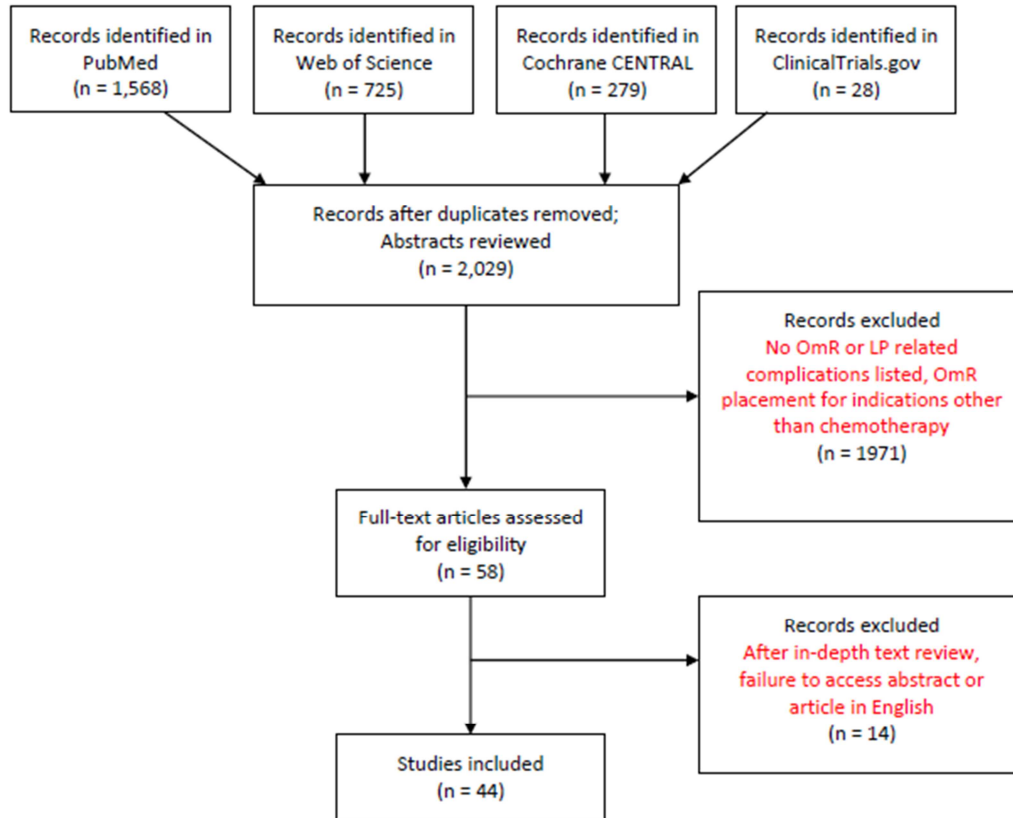


Figure 1. Prisma diagram of search strategy for systematic review.

3. Results

3.1. Retrospective Analysis

Between 01/2011 and 12/2016, a total of 936 patients underwent insertion of a neuro-ventricular device at the University of Florida. Of those, 22 had placement of an OmR; the remaining patients had ventricular-peritoneal shunt placement or revision procedures. Out of 22 patients, 13 devices were placed for intrathecal chemotherapy and 11 for hydrocephalus; 1 patient had a device placed for both reasons. Hence 13 patients were included in the retrospective review with their demographics shown (Table 1). Following OmR placement, patients were then followed retrospectively in four 6-month intervals during the post-operative period to analyze complication rates, from OmR placement to 6 months post-op, from 6 months to 1 year post-op, and from > 1 year post-op (Figure 2). We had a total of 63 OmR punctures with a mean of 5.7 punctures per patient. Two out of 13 patients encountered complications, making the event rate of complications 15.8%.

Event rate was defined as number of total complications in the period examined divided by total number of patients. Tables 2 and 3 show OmR specific data for all 13 patients, along with their expected survival.[13-19] Infectious and noninfectious complications are shown in Figure 2.

Table 1. Demographics data of patient population (n=13).

Gender	Male	7 (53.8%)
	Female	6 (46.2%)
Race	White	7 (53.8%)
	Black	5 (38.5%)
	Unknown	1 (7.7%)
Smoking history	Yes	5 (38.5%)
	No	8 (61.5%)
Age at placement (< or = 18)	Yes	1 (7.7%)
	No	12 (92.3%)
BMI (mean), Kg/m ²	29.2 (18.0-46.8)	
Comorbidities	Type II DM	3 (75%)
	CAD	1 (25%)
	HIV	1 (25%)

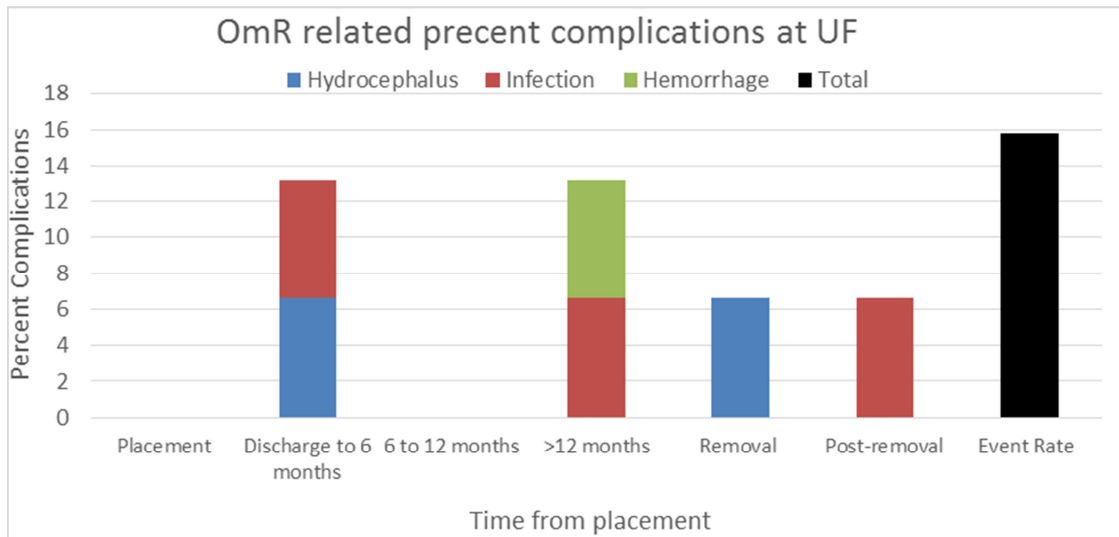


Figure 2. Complication percentage rate per time interval from Ommaya reservoirs used for chemotherapy. Complications included infection, hemorrhage, and hydrocephalus and time points evaluated included time of placement, discharge to 6 months, 6-12 months, >12 months, removal, and post removal. Also shown is event rate i.e. patients with complications/total number of patients.

Table 2. Cancer-specific demographic data of patient population (n=13).

Primary cancer diagnosis	Breast	2 (15.4%)
	AML	1 (7.7%)
	ALL	2 (15.4%)
	DLBCL	4 (30.8%)
	Burkitt's lymphoma	1 (7.7%)
	Other NHL	1 (7.7%)
	PCNSL	1 (7.7%)
	MM	1 (7.7%)
Cancer stage	Stage 3	1 (11.1%)
	Stage 4	7 (77.8%)
	Unstageable	1 (11.1%)
Type of IT chemotherapy	Ara-C	4 (36.4%)
	MTX	9 (81.8%)
	Other	2 (18.2%)
Median number of months (between diagnosis and OmR placement)	1	Range 1-108

AML: Acute Myelogenous Leukemia; ALL: Acute Lymphocytic leukemia; DLBCL: Diffuse Large B Cell Lymphoma; Burkitt's Lymphoma; NHL: Non-Hodgkin's Lymphoma; PCNSL: Primary CNS Lymphoma; MM: Multiple Myeloma; Ara-C: Cytarabine; MTX: Methotrexate

Table 3. Ommaya Reservoir (OmR) data at University of Florida.

Pt	Diagnosis	LM disease on diagnosis	Systemic Chemo	No. LP prior to OmR	OmR 2/2 LP complication	OmR access # (chemo given)	Median expected survival
1		No	R-CHOP	0	No	6 (6)	
2	DLBCL	Yes	R-MTX	1	No	1 (1)	2 to 6.5 mos [13]
3		Yes	R-EPOCH	0	No	1 (1)	
4		Yes	BR	0	No	1 (1)	
5	Other NHL	Yes	R	0	No	14 (16)	2.6 mos [14]
6	BL	Yes	R-EPOCH	1	No	1 (1)	NR
7	AML (r/r)	No	Ara-C, 2CdA, MTX	1	No	8 (8)	9.9 mos [15]
8	ALL (r/r)	Yes	MXT, V	0	No	9 (9)	4-6 wks [16]
9	ALL	No	Ara-C, R-MTX, LV	0	NR	2(4)	
10	PCNS	Yes	NR	0	NR	NR	2-3 mos [17]
10	MM (r/r)	No	Ara-C, CP, Mesna	1	No	2	7 mos [18]
11	BC (r/r)	Yes	NR	0	No	8	14.9-18.1 weeks [19]

LM: leptomeningeal disease, (r/r): relapsed and/or refractory, DLBCL: Diffuse Large B Cell Lymphoma; NHL: Non Hodgkin's Lymphoma; AML: Acute myelogenous leukemia; ALL: Acute lymphocytic leukemia; MM: Multiple Myeloma; PCNS: Primary CNS Lymphoma; BC: Breast Cancer; R-CHOP: Rituximab, Cyclophosphamide, Doxorubicin, Vincristine, Prednisone; R-MTX: Rituximab, Methotrexate; R-EPOCH: Rituximab, Etoposide, Prednisone, Vincristine, Cyclophosphamide, Doxorubicin; BR: Bendamustine, Rituximab; R: Rituximab; Ara-C: Cytarabine; 2CdA: Cladribine; MXT: Mitoxantrone; V: Vincristine; LV: Leucovorin; R: Rituximab; CP: Cyclophosphamide; MTX: Methotrexate; NR: Not Reported; months: mos; weeks: wks; n/a: not applicable (two additional patients had OmR placed but never accessed).

3.1.1. Non-infectious Complications

At the time of OmR placement to discharge, no patient had a catheter related non-infectious complication. From discharge to 6 months after placement, 1 (6.6%) patient had hydrocephalus requiring VP shunt. From 6 months to 12 months after placement, no patient had a catheter related non-infectious complication. At > 12 months after placement, 1 (6.6%) patient had an intracranial hemorrhage. At the time of OmR removal, 1 (6.6%) patient had hydrocephalus requiring VP shunt (of note, same patient who had hydrocephalus requiring VP shunt before). Post OmR removal, no patient had a catheter-related non-infectious complication. Average follow up time was 18 months.

3.1.2. Infectious Complications

At the time of OmR placement to discharge, no patient had a catheter related infectious complication. From discharge to 6 months after placement, 1 (6.6%) patient had a catheter related infection (pathogen could not be isolated). From 6 months to 12 months after placement, no patient had a catheter related infectious complication. At > 12 months after placement, 1 (6.6%) patient had a catheter related infectious complication (HSV encephalitis). At the time of OmR removal, no patient had a catheter related infectious complication. Post OmR removal, 1 patient (6.6%) developed HSV encephalitis. During our analysis, we found that no patients died due to

direct complication of OmR placement. 1 (6.6%) patient had OmR removed at completion of therapy. Our puncture to complication ratio was 10.5:1.

3.2. Systematic Review

A total of 38 studies focusing on OmR and related complications were read in full and included in the review based on inclusion and exclusion criteria outlined in the methods section (Table 4). [2, 3, 7, 9-11, 20-51] A total of 8 studies focusing on the complications of LP administration of intrathecal agents were also analyzed and used in this review for comparison (Table 5). [29, 33, 52-57] Collectively, these studies analyzed a total of 3771 OmRs and 1721 LP unique administrations. All patients received either OmR placement or repeated lumbar punctures for chemotherapy treatment (Cytarabine, Methotrexate, Thiotepe). The OmR studies were stratified into short term studies (if less than 10 years duration) and long term studies (if greater than 10 years). 1831 patients were included in the short term studies and 1940 patients were included in the long term studies. The rate of complications related to device placement or serial lumbar puncture was analyzed. Complications were further divided into non-infectious (such as CSF leaks, catheter malposition) and infectious causes.

Table 4. Literature review of Ommaya Reservoir (OmR) infectious and non-infectious complications in alphabetical order.

Reference	N	Age	Data collection period	Diagnosis	# of OmR access
Berweiler [20]	70	NR	NR	NR	NR
Boiardi [21]	276 (65 with OmR)	19-70	2 years	65 GBM	NR
Browne [22]	61	1-26	10 years	49 Leukemia 8 Lymphoma 4 Solid tumor	43.5 (1-176)
Chamberlain [23]	15	23-46	5 years	11 NHL 4 PCNS 34 Breast 22 NHL 16 Melanoma 10 Neuroectodermal	400
Chamberlain [7]	120	10-72	10 years	6 Glial 6 Leukemia 6 Lung 6 Colorectal 3 Prostate 3 Renal 2 Gastric	4400 40 (10-86) per pt
Chamberlain [24]	18	28-70	11 years	10 Anaplastic astrocytoma 8 GBM 12 Medulloblastoma 3 CNS PNET	NR
Gerber [10]	20	1-11	15 years	3 Atypical Teratoid 1 GBM 1 Malignant melanocytic	461
Green [25]	27	1-17	1.5 years	27 ALL 63 Lung	NR
Gwak [26]	155 (89 OmR)	15-76	7 years	18 Breast 8 Other	NR
Haaxma-Reiche [27]	28	17-73	NR	28 AML	NR
Haghbin [28]	27	NR	5 years	27 CNS ALL	NR
Iacoangeli [29]	9	15-61	7 years	9 ALL with CNS involvement	262, 29 per patient (18-49)
Lau [30]	55	27-60	4 years	30 ALL	NR

Reference	N	Age	Data collection period	Diagnosis	# of OmR access
Lavrador [11]	23	56 (median)	8 years	16 DLBCL 5 Leptomeningeal carcinomatosis 2 Burkitt's Lymphoma 1 CML 1 TCL 16 Breast 4 Lung 1 Stomach 1 Bladder 1 Cervix 27 ALL 12 AML	NR
Lishner [2]	106	17-79	5 years	3 CLL 34 Lymphoma 29 Carcinoma 1 CML 90 PCNSL 80 CNS Solid Tumor	NR
Mead [31]	616	44.5 (median)	16 years	4 Head & Neck 137 Leukemia 175 Lymphoma 152 Other Solid tumors 107 Breast 86 Leukemia 79 Lymphoma 36 Lung 16 Melanoma 26 Brain	NR
Obbens [32]	387	15mos - 79 y	15 years	4 Medulloblastoma 2 Nueroblastoma 9 Urogenital 3 Colorectal 8 Sarcoma 7 Adenocarcinoma (unknown primary) 4 Miscellaneous	1 - 55 x (9.5 per patient)
Pardo Moreno [33]	16	18-84	NR	12 with leptomeningeal disease	4
Pels [9]	65	27-75	6 years	62 NHL 30 ALL 14 AML	NR
Perrin [34]	120	11-79	NR	3 CLL 2 CML 39 Lymphoma 32 Carcinoma 26 Medulloblastoma 16 CNS PNET 14 Ependymoma 8 Pineoblastoma 4 GBM 3 CNS germ cell 2 Choroid Plexus	NR
Peyrl [35]	98	3 months to 21 y/o	20 years	1 Anaplastic astrocytoma 1 Central neurocytoma 1 Cerebral rhabdomyocardoma 1 PCNSL 1 Ependymblastoma 1 Desmoplastic infantile ganglioma 1 epitheloid sarcoma	36/pt (2-280)
Pompe [36]	240 (211 OmR)	0.22-20.31	7 years	211 Medulloblastoma 5 Craniopharyngioma 5 Resistant meningeal leukemia 5 Cystic tumors	NR
Ratcheson [3]	60	NR	6 years	18 GBM 1 Benign intraventricular tumor 1 Sarcoma 2 Lymphoma	NR
Roguski [37]	80	54-59	11 years	24 Lymphoma 23 Breast	NR

Reference	N	Age	Data collection period	Diagnosis	# of OmR access
Sampath [38]	18 OmR	16-78 (mean 44.6)	2 years	14 Lung	NR
				9 Leukemia	
Sandberg [39]	107	1-83 y	3.5 years	4 Primary CNS	NR
				1 Melanoma	
Schlegel [40]	20; 19 OmR	27-71	3 years	2 Ovarian	NR
				2 Other	
Siegal [41]	66	NR	7 years	1 Unknown	NR
				NR	
Steinherz [42]	39	0.5-15	10 years	46 Lymphoma	NR
				32 Leukemia	
Stewart [43]	23 (20 OmR)	19-74	NR	20 Breast	NR
				2 Melanoma	
Szvalb [44]	501	6-77	10 years	2 Lung	NR
				2 Medulloblastoma	
Takahashi [45]	77	17-79	21 months	1 Esophageal	NR
				1 Germ cell	
Weiner [46]	28	28.2-86.9	4 years	1 Neuroblastoma	NR
				20 PCNSL	
Yoshida [47]	58	25-76	Jan 1993-Aug 2002	61 Leptomeningeal metastases	NR
				5 SSPE	
Young [48]	19	14-65	8 years	39 ALL	NR
				7 Lymphoma	
Zairi [49]	50	28-70	3 years	4 Small cell lung	NR
				3 Adeno (lung)	
Zairi [50]	112	26-73	6 years	3 Breast cancer	NR
				1 Medulloblastoma	
Zhang [51]	45	NR	3.5 years	1 GBM	NR
				NR	

Table 4. Continue.

Reference	Non-infectious complications	Infectious complications	OmR interventions	Median survival
Berweiler [20]	2 Obstruction (2.9%) 12 Seizures (4%) 6 Headaches (2%)	3 Meningitis (4.3%) (1 <i>S. epi</i>)	NR	NR
Boiardi [21]	5 Drowsiness (1.8%) 4 Transient focal deficit (1.4%) 6 Hemorrhage (6%)	8 Skin infection (6 developed abscess) (12.3%)	8 Removed	11 months (9-13)
Browne [22]	4 Malfunction	14 <i>P. acnes</i> (23%) 12 Asymptomatic meningitis	9 Removed	NR
Chamberlain [23]	4 Aseptic meningitis (27%) 13 Cytopenia (87%) 52 Aseptic meningitis (43%) 21 Myelosuppression (17.5%)	2 NR (13%)	2 Removed	125 days (44-260)
Chamberlain [7]	6 Catheter obstruction (5%) 2 OmR exposure (1.7%) 2 Leukoencephalopathy (1.7%)	9 <i>S. epidermidis</i> meningitis (7.5%)	5 Removed	NR
Chamberlain [24]	12 Aseptic arachnoiditis (66.7%) 4 myelosuppression (22.2%) 6 Wound Dehiscence (30%) 3 Malplacement (15%)	NR	NR	3.5 (2-8 months)
Gerber [10]	1 Subcutaneous CSF collection (5%) 1 CSF leakage (5%) 1 Hydrocephalus (5%)	7 Coagulase negative <i>Staphylococcus</i> (35%)	17 Removed	155 days (2-2871)
Green [25]	3 Leukoencephalopathy (11.1%)	2 <i>S. epidermidis</i> (7.4%) 1 <i>Diphtheriae</i> (3.7%)	3 Removed	NR
Gwak [26]	12 CSF leakage (7.7%) 3 Intracranial hemorrhage (1.9%)	13 infection (0.83%)	12 Removed	NR
Haaxma-Reiche [27]	1 Focal neurologic deficit 3.6%	3 <i>Diphtheriae</i> (10.7%) 1 <i>S. epidermidis</i> (3.6%) 1 <i>S. epidermidis</i> (3.7%) 1 <i>P. acne</i> (3.7%)	None	22%
Haghbin [28]	2 Migration (7.4%)	1 reservoir infection (11%)	1 Removed	NR
Iacoangeli [29]	1 CSF leakage (11%) 1 leukoencephalopathy (11%)	2 Reservoir infection (3.6%) (1 <i>S. epidermidis</i>)	2 Removed	152 weeks
Lau [30]	4 Malposition (7.3%), 3 Hemorrhage (5.5%)	0 complications	5 Removed	NR
Lavrador [11]	0 complications	13 Bacterial Meningitis (12.2%) (1 <i>S. aureus</i> 8 Coag neg staph 2 <i>P. acne</i> 1 <i>Diphtheriae</i> 1 <i>C. Parapsillosis</i>)	NR	26.4 weeks(+/- 7.7 weeks)
Lishner [2]	1 Misplacement 1 (0.9%) 3 ICH 3 (2.8%) 5 Malfunction (4.7%) 1 subdural hygroma (0.9%)	28 Definite Infection (4.5%) 6 Possible Infection (0.9%) (5.5%) (19 Coag neg staph 1 <i>S. aureus</i> 2 <i>S. viridans</i> 1 <i>E. faecalis</i> 8 <i>P. acne</i> 2 <i>L. monocytogenes</i> 1 <i>P. aeruginosa</i>)	4 Removed	NR
Mead [31]	NR	19 Infections (4.9%) 12 <i>S. epidermidis</i> 2 <i>S. aureus</i> 1 <i>S. pyogenes</i> 1 <i>E. coli</i> 1 <i>P. aeruginosa</i> 1 <i>C. albicans</i> 1 <i>C. neoformans</i>	17 Removed	NR
Obbens [32]	5 ICH (1.3%) 2 Cerebral edema (5.2%) 3 Seizures (7.8%) 15 Failure/malfunction (3.9%) 5 Leukoencephalopathy (1.3%) 2 Pericatheter necrosis (0.5%)	12 <i>S. epidermidis</i> 2 <i>S. aureus</i> 1 <i>S. pyogenes</i> 1 <i>E. coli</i> 1 <i>P. aeruginosa</i> 1 <i>C. albicans</i> 1 <i>C. neoformans</i>	15 Removed	NR
Pardo Moreno [33]	NR	NR	NR	NR
Pels [9]	NR	12 NR 12 Infectious (10%) (1 <i>S. aureus</i> 1 <i>S. epidermidis</i> 2 Diptheroids 2 <i>P. acne</i>)	12 Removed	> 60, 34 months, <61, NR
Perrin [34]	11 Technical Complications (9%)	NR	4 Removed 3 Revised	NR

Reference	Non-infectious complications	Infectious complications	OmR interventions	Median survival
		2 <i>S. homonyous</i> 2 <i>C. parapsillosis</i>		
Peyrl [35]	1 Malposition (1%) 3 Catheter dysfunction (3%) 6 Aseptic chemical meningitis (6%) 19 Malfunction (9%)	1 Inection (1%) (<i>S. epidermidis</i> and <i>B. cereus</i>)	1 Removed 3 Revised	3.7 years (1 mo - 20 yrs)
Pompe [36]	1 ICH (0.5%) 1 Asymptomatic parenchymal damage (0.5%) 11 CSF leakage (5%) 1 Failed implantation (0.5%) 8 Malfunction (13.3%)	32 Infection (16%) (<i>S. epidermidis</i> , <i>S. aureus</i>)	39 Removed	5 year overall survival 70%
Ratcheson [3]	5 seizures (8.3%) 1 Leukoencephalopathy (1.7%) 2 Aseptic meningitis (3.3%)	Infections (16.7%) 4 Bacterial meningitis 5 + CSF cultures 1 Cellulitis	15 Revised 4 Removed	NR
Roguski [37]	NR 6 Overall complications (15.8%)	NR 6 Overall complications (15.8%) (<i>P. acne</i> and <i>S. epidermidis</i>)	NR	72.5 days (36-122)
Sampath [38]	1 Malposition (5.6%)	NR for ommaya group	1 Revised 8 Converted to VP shunts	NR
Sandberg [39]	5 Malposition (4.7%) 3 ICH (2.8%) 2 Leukoencephalopathy (1.9%)	2 Gram + infection (1.9%)	5 Revised 2 Removed	8.54 mos
Schlegel [40]	1 hemorrhage (5%)	4 Infection (21%) 8 Infections (12%)	3 Removed	54 mos
Siegal [41]	NR	(3 Coag positive Staph, 3 Coag negative Staph, 1 Diphtheroid, 1 <i>K pneumoniae</i>)	0 Removed	NR
Steinherz [42]	2 Catheter tip displament (5.2%) 4 Decreased level of consciousness (20%) 3 Leukoencephalopathy (15%) 1 Confusion (5%) 1 Ascending quadriplegia (5%) 3 Seizures (15%) 1 Burning sensation in back (5%) 1 Paresthesias (5%)	3 Infection (7.7%) 1 Local cellulitis (2.6%)	3 Removed	25 mos
Stewart [43]	10 Neurological complications (50%) 9 Myelosuppression (45%) 5 Stomatitis (25%) 5 Nausea/vomiting (25%) 3 Headache (15%) 3 Back/limb pain (15%) 2 Meningismus (10%) 3 Diarrhea (15%) 3 OmR blockage (15%)	1 Fever (5%) 1 Meningitis (5%)	NR	21 mos
		40 Infections (8%) (6 polymicrobial, 28 Coag neg Staph, 4 <i>P. acne</i> 4 MSSA 3 <i>S. pyogenes</i> 1 Cornebacterium species		
Szvalb [44]	NR	1 <i>E. faecalis</i> 1 MRSA 4 Psuedomonas species 1 <i>E. aerogenes</i> 1 <i>E. coli</i> 1 <i>B. fragilis</i> 1 Non-typable Haemophili 1 <i>K. pneumoniae</i> 1 <i>C. albicans</i>)	29 Removed	NR
Takahashi [45]	1 Malposition (1.2%)	0	1 Revised	NR
Weiner [46]	1 Edema (3.6%)	1 Infection (3.6%)	0	NR
Yoshida [47]	NR	NR	NR	Lymphoma 32 mos Lung 10.5 mos

Reference	Non-infectious complications	Infectious complications	OmR interventions	Median survival
Young [48]	2 seizures (11.7%) 3 encephalopathy (15.8%) 1 cranial nerve palsy (5.3%)	6 Infections (35.3%) (3 <i>S. epidermidis</i> 2 <i>S. aureus</i> 1 <i>Diphtheriae</i>)	2 Removed	Breast 10.8 mos Other 8.7 mos 8 months
Zairi [49]	1 Hemorrhage (2%) 2 Edema (4%)	2 Infections (4%)	3 Removed	7 months
Zairi [50]	2 Leukoencephalopathy (1.8%) 1 Intracranial hemorrhage (0.9%) 1 Malpositioned catheter (0.9%)	3 Surgical site infections (2.7%) 3 Meningitis (2.7%) 1 SQ sterile inflammatory fluid collection 3 MSSA (3.6%) 1 <i>S. epidermidis</i> (0.9%) 1 <i>P. acne</i> (0.9%)	6 Removed	NR
Zhang [51]	NR	NR	1 Revised	NR

NR: Not reported; GBM: Glioblastoma; DLBCL: Diffuse Large B Cell Lymphoma; NHL: Non Hodgkin's Lymphoma; AML: Acute myelogenous leukemia; ALL: Acute lymphocytic leukemia; CML: Chronic myelogenous leukemia; CLL: Chronic lymphocytic leukemia; MM: Multiple Myeloma; PCNSL: Primary central nervous system lymphoma; PNET: primitive neuroectodermal tumor; CNS: Central nervous system; CSF: Cerebrospinal fluid; TCL: T cell lymphoma; ICH: Intracranial hemorrhage; SSPE: Subacute sclerosing panencephalitis; NSCLC: non-small cell lung cancer.

Table 5. Literature review of Lumbar Puncture infectious and non-infectious complications in alphabetical order.

Reference	N	Age Range	Data collection period	Diagnosis	Non-infectious complications	Infectious complications	Median survival
Foerster [52]	440	1 month - 20.9 years	7 years 9 months	ALL NHL AML Other 6 Medulloblastoma 2 Germinomas	0	NR	NR
Gaviani [53]	12	20-45	5 years	1 Ependymoma 1 Teratocarcinoma 1 Meningeal melanoma 1 Pylocytic astrocytoma	5 Transient local back pain (41.7%) 1 Arachnoiditis (8.3%) 3 transient headaches (25%)	NR	NR
Gonzalez-Barca [54]	18	18-80	5 years	24 DLBCL	3 Headaches (16.7%) 1 Dizziness (5.6%) 1 Confusion (5.6%) 1 Nausea/Vomiting (5.6%)	NR	3 year OS 80.8%, 3 year PFS 70.7%
Howard [55]	958	1 month to 18 years	14 years	ALL	0	NR	NR
Iacoangel [29]	12	15-70	7 years	ALL	1 CSF leak (8.3%) 1 chemical arachnoiditis (8.3%) 2 technical difficulties due to repeated punctures (16.7%)	NR	14 weeks
Jaeckle [56]	110	19-77	9 months	38 Breast 4 SCLC 14 NSCLC 14 Melanoma 20 Brain 20 Other	47 Headache (42.7%) 41 Nausea (37.3%) 37 Vomiting (33.6%)	NR	NR
Keidan [57]	47	1-16	18 month	42 ALL 5 AML	7 Nausea/Vomiting (14.9%) 5 Back pain (10.6%) 7 Post dural puncture headache (14.9%) 4 Headache (8.5%) 10 Hydrocephalus (21.3%) 3 Major neurological complications (6.4%) 1 Transient brainstem syndrome (0.8%)	NR	NR
Pardo Moreno [33]	124	18-84	5 years	5 Breast 2 Other solid 77 Lymphoma 38 Leukemia 2 Other liquid	2 Retinal hemorrhages (1.6%) 1 Epidural hematoma (0.8%) 7 Moderate-intense orthostatic headache (5.6%) 2 Chemical meningitis (1.6%)	1 Infectious meningitis (0.8%) 1 Infectious ventriculitis (0.8%)	NR

Reference	N	Age Range	Data collection period	Diagnosis	Non-infectious complications	Infectious complications	Median survival
					2 Subdural hygromas (1.6%) 4 Recurrent chemical ventriculitis (3.2%) 3 Leukoencephalopathy (2.4%) 3 Arachnoiditis (2.4%) 3 Device malfunction (2.4%) 1 Vertigo syndrome (0.8%) 1 Myelopathy (0.8%) 8 Mild orthostatic headache (6.5%) 5 Recurrent orthostatic headached (4.0%) 3 Vaso-vagal reaction (2.4%) 6 Irritative radiculopathy (4.8%) 2 Increase in migraines (1.6%) 3 Intracranial hypertension (2.4%)		

NR: Not reported; DLBCL: Diffuse Large B Cell Lymphoma; NHL: Non Hodgkin's Lymphoma; AML: Acute myelogenous leukemia; ALL: Acute lymphocytic leukemia; NSCLC: Non-small cell lung cancer; SCLC, Small cell lung cancer.

3.2.1. Non-infectious Complications

The most common non-infectious complications reported in the studies were catheter malposition or malfunction, neurological complications (seizures, focal neurological deficits, or cranial nerve palsies), and CSF leakage. In the short term Ommaya reservoir studies, 158 total complications were identified (8.63% complication rate); 30 of these were associated with catheter malposition/malfunction, 28 from neurological complications, 24 from CSF leakage, and 15 from intracranial hemorrhage. In the long-term Ommaya studies, 66 total complications were identified (3.4% complication rate); 30 of these were due to catheter malposition/malfunction, 7 from leukoencephalopathy, and 5 from intracranial hemorrhage. There was no statistical difference between those rates ($P = 0.2919$).

Lumbar puncture non-infectious complications were much more common than infectious complications. Out of a total of 1721 unique punctures, there were 201 complications. The most frequent complications reported were headaches (77/201) and nausea/vomiting (49/201); however, more serious complications included epidural hematomas, chemical arachnoiditis, and increased intracranial hypertension.

3.2.2. Infectious Complications

The rate of infectious complications throughout all studies focusing on OmR ranged widely from 0% to 35% over the duration of OmR implantation. These studies spanned a greater than 20-year period and remarkably there was no significant difference in observed infection rates (>10 years ago 1-35%, <10 years ago 0-31.5%; $P=0.5169$). This stratification was based on a relative time to implementation of infection prevention bundles to show reduction in transmission. However, the wide variability between implementation of these between centers likely contributed to the lack of significant improvement. The pathogens most commonly implicated in infectious complications consisted of *Staphylococcus epidermidis* and *Staphylococcus aureus*, followed by *Diphtheroid bacilli* and *Propionibacterium acnes*.

Of the 146 infections reported in the short-term ommaya reservoir studies, 36 of them were identified from *S. epidermidis*, and 13 from *S. aureus*. Of the 127 infections reported in the long-term OmR studies, 77 were identified from *S. epidermidis*, 14 from *P. acnes*, and 7 from *S. aureus*.

In contrast, LP infectious complications ranged from 0% to 1.6% over the course of treatment. Only one study identified infectious complications directly related to LP method of delivery, although no species were identified. The rate of non-infectious complications ranged from 1% to 60%. Similar stratification based on length of study was done; studies greater than 10 years in length found a non-infectious complication rate between 5% and 60%, whereas studies less than 10 years in length found a complication rate between 1% and 39%. Interestingly, there were no delays in chemotherapy delivery reported in any of the studies due to difficulty in intrathecal access via lumbar puncture.

Statistical analysis of infectious complications between OmR and LP studies, not stratified based on length of study, yielded a significant difference. OmR studies showed a statistically significant increase in infectious complications rates. The average percentage of infectious complications of OmR per study was $10.9\% \pm 1.6$, and the average percentage of infectious complications of LPs per study was $0.2\% \pm 0.2$, with $P=0.0017$. In contrast, analysis of non-infectious complications between OmR and LP studies yielded the opposite effect; LP studies showed a statistically significant increase in non-infectious complication rates. The average percentage of non-infectious complications of OmR per study were $12.68\% \pm 2.6$, and the average percentage of non-infectious complications of LPs per study was $43.13\% \pm 11.5$, with $P=0.0004$.

4. Discussion

OmRs as a route of drug administration play a central role in the management of neuro-oncologic diseases. This method of drug administration has been used frequently over the past few decades. Despite their routine use, the placement of these

devices can still be associated with significant morbidity and mortality. Our results suggest that these devices, while more prone to infectious complications compared to the more traditional lumbar puncture administration, appear to be a safe delivery method.

Our retrospective study identified 6 complications in 13 patients with an OmR, with a complication rate of 46%. HSV encephalitis was the most common infectious complication, seen 2 out of 13 times with a complication rate of 15%. Hydrocephalus was the most common non-infectious complication, seen 2 out of 13 times with a complication rate of 15%. For 1 (7%) infectious complication, pathogen was not isolated.

In contrast to our center's experience, several similar studies from other centers have shown the majority of the infectious complications tend to originate from skin flora, such as *S. epidermidis* and *S. aureus*, [31, 2] and the use of strict antiseptic measures has significantly reduced these complications. [35] We account for this discrepancy largely by the small sample in our study, implementation of newer infection bundles, and improved and more precise device placement techniques [10] Some of the studies analyzed in this review are more than 10-15 years old, and surgical/antiseptic measures and techniques have significantly improved since then. This might lead to slightly higher rates of infectious complications in some of the longer studies.

Stratifying the Ommaya reservoir and LP groups based on the length of the studies did not yield a meaningful difference in rates of complications. Based on results from our institution, infectious and non-infectious complication rates were spread evenly across the time of placement to post-OmR removal. However, the studies we reviewed did not specify when precisely the infective complications occurred. As explained above, some of the long-term studies are more than 10-20 years old and surgical techniques have improved since then, possibly leading to bias. We also recognize that certain practitioners may have different experience based on the number of devices they have implanted, possibly adding operator bias as well.

We included only OmR complication data in our single-center retrospective review as studies are underway looking at LP complication rates in the setting of IT chemotherapy delivery by either oncologists or interventional radiologists. We reviewed this data and included the systematic review because there is a dearth of data comparing OmR and LP complication rate in the setting of IT chemotherapy delivery. We wanted to determine if the complication rate was significantly higher in one group versus the other, and if that difference should be practice changing.

The Ommaya reservoir placement group suffered significantly increased rates of infection complications when compared to the LP group. The Ommaya reservoir placement procedure is much more invasive and leads to long-term implantation of a foreign object, making infection much more likely. However, the LP group had significantly more non-infectious complications, most likely due to repeated trauma over a long period of time through the intrathecal space.

As was previously reported, a very useful indicator for

analyzing the rates of infectious complications for Ommaya reservoirs is the puncture to complication ratio (and for our study, that ratio was 10.5:1). Given that most infectious complications tend to be from skin flora, punctures to access the reservoir could be a very significant source of those infections. Unfortunately, most studies we analyzed did not adequately measure the number of punctures per patient, and some did not report it at all.

We used expected survival for the retrospective analysis to principally control for individual comorbidities and to account for a small sample size. The range of expected survival was 4 weeks to 9.9 months, which shows that these patients have an extremely limited prognosis and any aggressive therapy (if complications are acceptable) can add significantly to the overall lifespan. In our study, we observed a 10.5:1 puncture to complication ratio and we think that risk may be acceptable given the limited life span.

5. Conclusion

In this retrospective study and review, we compared complication rates from infectious and non-infectious sources between patients receiving intrathecal chemotherapy through Ommaya reservoirs versus lumbar puncture. Patients with Ommaya reservoirs were much more likely to suffer an infectious complication (specifically HSV encephalitis) with a puncture to complication ratio of 10.5:1 and much less likely to suffer a non-infectious complication compared to patients with repeated lumbar punctures. Although the puncture to complication ratio may seem unfavorable, patients that would benefit from Ommaya reservoir placement typically have significant morbidity and have limited lifespan, rendering placement and use of these devices an acceptable risk. Surgeons and clinicians should take these factors into account when caring for this patient population.

Author Contributions

AA, RDB performed literature search, created study design, drafted the manuscript, performed data collection and analysis, and approved the final version of the manuscript.

BPD, PN, GAJ, JDD, JLB, SLW performed literature search, created study design, data collection, data analysis, critically revised the manuscript, and approved the final version of the manuscript.

HFN provided search strategies for the systematic review, critically reviewed the manuscript, and approved the final version of the manuscript.

CDH created study design, supervised data collection and analysis, critically revised the manuscript, and approved the final version of the manuscript.

Competing Interest Statement

The authors report no competing interests involved in the design of the study, data collection, or the drafting of the manuscript.

Acknowledgements

This work was supported by the Gatorade Trust through funds distributed by the University of Florida, Department of Medicine (CDH).

References

- [1] Ommaya AK (1963) Subcutaneous reservoir and pump for sterile access to ventricular cerebrospinal fluid. *Lancet* 2 (7315): 983-984.
- [2] Lishner M, Perrin RG, Feld R, Messner HA, Tuffnell PG, Elhakim T, Matlow A, Curtis JE (1990) Complications associated with Ommaya reservoirs in patients with cancer. The Princess Margaret Hospital experience and a review of the literature. *Arch Intern Med* 150 (1): 173-176.
- [3] Ratcheson RA, Ommaya AK (1968) Experience with the subcutaneous cerebrospinal-fluid reservoir. Preliminary report of 60 cases. *N Engl J Med* 279 (19): 1025-1031. doi: 10.1056/NEJM196811072791904.
- [4] Cornwell CM (1990) The Ommaya Reservoir: implications for pediatric oncology. *Pediatr Nurs* 16 (3): 249-251.
- [5] Filis A, Kalakoti P, Connor DE, Nanda A (2016) Elucidating the utility of neuro-navigation in reducing malposition rates in Ommaya reservoir placement: 23-year operative experience at the Louisiana State University. *Neurol India* 64 (6): 1195-1201. doi: 10.4103/0028-3886.193798.
- [6] Cohen-Pfeffer JL, Gururangan S, Lester T, Lim DA, Shaywitz AJ, Westphal M, Slavo I (2017) Intracerebroventricular Delivery as a Safe, Long-Term Route of Drug Administration. *Pediatr Neurol* 67: 23-35. doi: 10.1016/j.pediatrneurol.2016.10.022.
- [7] Chamberlain MC, Kormanik PA, Barba D (1997) Complications associated with intraventricular chemotherapy in patients with leptomeningeal metastases. *J Neurosurg* 87 (5): 694-699. doi: 10.3171/jns.1997.87.5.0694.
- [8] Pels H, Schmidt-Wolf IG, Glasmacher A, Schulz H, Engert A, Diehl V, Zellner A, Schackert G, Reichmann H, Kroschinsky F, Vogt-Schaden M, Egerer G, Bode U, Schaller C, Deckert M, Fimmers R, Helmstaedter C, Atasoy A, Klockgether T, Schlegel U (2003) Primary central nervous system lymphoma: results of a pilot and phase II study of systemic and intraventricular chemotherapy with deferred radiotherapy. *J Clin Oncol* 21 (24): 4489-4495. doi: 10.1200/JCO.2003.04.056.
- [9] Pels H, Juergens A, Glasmacher A, Schulz H, Engert A, Linnebank M, Schackert G, Reichmann H, Kroschinsky F, Vogt-Schaden M, Egerer G, Bode U, Schaller C, Lamprecht M, Hau P, Deckert M, Fimmers R, Bangard C, Schmidt-Wolf IG, Schlegel U (2009) Early relapses in primary CNS lymphoma after response to polychemotherapy without intraventricular treatment: results of a phase II study. *J Neurooncol* 91 (3): 299-305. doi: 10.1007/s11060-008-9712-4.
- [10] Gerber NU, Müller A, Bellut D, Bozinov O, Berger C, Grotzer MA (2015) Ventricular Catheter Systems with Subcutaneous Reservoirs (Ommaya Reservoirs) in Pediatric Patients with Brain Tumors: Infections and Other Complications. *Neuropediatrics* 46 (6): 401-409. doi: 10.1055/s-0035-1565271.
- [11] Lavrador JP, Simas N, Oliveira E, Carvalho MH (2016) [Intratechal Chemotherapy Treatment Through an Ommaya Reservoir Catheter for Meningeal Carcinomatosis: A Single-Centre Experience]. *Acta Med Port* 29 (7-8): 456-460.
- [12] Harris PA, Taylor R, Thielke R, Payne J, Gonzalez N, Conde JG (2009) Research electronic data capture (REDCap)--a metadata-driven methodology and workflow process for providing translational research informatics support. *J Biomed Inform* 42 (2): 377-381. doi: 10.1016/j.jbi.2008.08.010.
- [13] Herr M, Barr P, Rich D, Mohile N (2014) Clinical Features, Treatment, and Survival of Secondary Central Nervous System Lymphoma. vol 124. *Blood*.
- [14] Nayar G, Ejikeme T, Chongsathidkiet P, Elsamadicy AA, Blackwell KL, Clarke JM, Lad SP, Fecci PE (2017) Leptomeningeal disease: current diagnostic and therapeutic strategies. *Oncotarget* 8 (42): 73312-73328. doi: 10.18632/oncotarget.20272.
- [15] Kwon JH, Koh YI, Yoon SS, Park S, Kim I (2016) Clinical outcome and efficacy of current anti-leukemic therapy for leptomeningeal involvement in acute myeloid leukemia. *Int J Hematol* 104 (5): 574-581. doi: 10.1007/s12185-016-2063-6.
- [16] Jabbour E, Thomas D, Cortes J, Kantarjian HM, O'Brien S (2010) Central nervous system prophylaxis in adults with acute lymphoblastic leukemia: current and emerging therapies. *Cancer* 116 (10): 2290-2300. doi: 10.1002/ncr.25008.
- [17] Shah A, Redhu R, Nadkarni T, Goel A (2010) Supratentorial glioblastoma multiforme with spinal metastases. *J Craniovertebr Junction Spine* 1 (2): 126-129. doi: 10.4103/0974-8237.77678.
- [18] Jurczynski A, Grzasko N, Gozzetti A, Czepiel J, Cerase A, Hungria V, Crusoe E, Silva Dias AL, Vij R, Fiala MA, Caers J, Rasche L, Nooka AK, Lonial S, Vesole DH, Philip S, Gangatharan S, Druzdz-Sitek A, Walewski J, Corso A, Cocito F, Vekemans MC, Atilla E, Beksac M, Leleu X, Davila J, Badros A, Aneja E, Abildgaard N, Kastiritis E, Fantl D, Schutz N, Pika T, Butrym A, Olszewska-Szopa M, Usnarska-Zubkiewicz L, Usmani SZ, Nahi H, Chim CS, Shustik C, Madry K, Lentzsch S, Swiderska A, Helbig G, Guzicka-Kazimierzczak R, Lendvai N, Waage A, Andersen KT, Murakami H, Zweegman S, Castillo JJ (2016) Central nervous system involvement by multiple myeloma: A multi-institutional retrospective study of 172 patients in daily clinical practice. *Am J Hematol* 91 (6): 575-580. doi: 10.1002/ajh.24351.
- [19] Scott BJ, Oberheim-Bush NA, Kesari S (2016) Leptomeningeal metastasis in breast cancer - a systematic review. *Oncotarget* 7 (4):3740-3747. doi: 10.18632/oncotarget.5911.
- [20] Berweiler U, Krone A, Tonn JC (1998) Reservoir systems for intraventricular chemotherapy. *J Neurooncol* 38 (2-3):141-143
- [21] Boiardi A, Silvani A, Eoli M, Lamperti E, Salmaggi A, Gaviani P, Fiumani A, Botturi A, Falcone C, Solari A, Filippini G, Di Meco F, Broggi G (2008) Treatment of recurrent glioblastoma: can local delivery of mitoxantrone improve survival? *Journal of Neuro-Oncology* 88 (1):105-113. doi: 10.1007/s11060-008-9540-6.
- [22] Browne MJ, Dinndorf PA, Perek D, Commers J, Bleyer WA, Poplack DG, Pizzo PA (1987) Infectious complications of intraventricular reservoirs in cancer patients. *Pediatr Infect Dis J* 6 (2): 182-189.

- [23] Chamberlain MC, Dirr L (1993) Involved-field radiotherapy and intra-Ommaya methotrexate/cytarabine in patients with AIDS-related lymphomatous meningitis. *J Clin Oncol* 11 (10): 1978-1984. doi: 10.1200/jco.1993.11.10.1978.
- [24] Chamberlain MC (2003) Combined-modality treatment of leptomeningeal gliomatosis. *Neurosurgery* 52 (2): 324-329. doi: 10.1227/01.Neu.0000043929.31608.62.
- [25] Green DM, West CR, Brecher ML, Ettinger LJ, Bakshi S, Berger P, Parthasarathy KL, Freeman AI (1982) The use of subcutaneous cerebrospinal fluid reservoirs for the prevention and treatment of meningeal relapse of acute lymphoblastic leukemia. *Am J Pediatr Hematol Oncol* 4 (2): 147-154.
- [26] Gwak HS, Lee CH, Yang HS, Joo J, Shin SH, Yoo H, Lee JS, Lee SH (2011) Chemoport with a non-collapsible chamber as a replacement for an Ommaya reservoir in the treatment of leptomeningeal carcinomatosis. *Acta Neurochirurgica* 153 (10):1971-1978. doi: 10.1007/s00701-011-1086-2.
- [27] Haaxma-Reiche H, Daenen S, Witteveen RJ (1988) Experiences with the Ommaya reservoir for prophylaxis and treatment of the central nervous system in adult acute myelocytic leukemia. *Blut* 57 (6): 351-355.
- [28] Haghbin M, Galicich JH (1979) Use of the Ommaya reservoir in the prevention and treatment of CNS leukemia. *Am J Pediatr Hematol Oncol* 1 (2): 111-117.
- [29] Iacoangeli M, Roselli R, Pagano L, Leone G, Marra R, Pompucci A, Trignani R, Scerrati M (1995) Intrathecal chemotherapy for treatment of overt meningeal leukemia: comparison between intraventricular and traditional intralumbar route. *Ann Oncol* 6 (4): 377-382.
- [30] Lau JC, Kosteniuk SE, Macdonald DR, Megyesi JF (2018) Image-guided Ommaya reservoir insertion for intraventricular chemotherapy: a retrospective series. *Acta Neurochir (Wien)* 160 (3): 539-544. doi: 10.1007/s00701-017-3454-z.
- [31] Mead PA, Safdieh JE, Nizza P, Tuma S, Sepkowitz KA (2014) Ommaya reservoir infections: a 16-year retrospective analysis. *J Infect* 68 (3): 225-230. doi: 10.1016/j.jinf.2013.11.014.
- [32] Obbens EA, Leavens ME, Beal JW, Lee YY (1985) Ommaya reservoirs in 387 cancer patients: a 15-year experience. *Neurology* 35 (9): 1274-1278.
- [33] Pardo-Moreno J, Fernández C, Arroyo R, Ruiz-Ocaña C, Aláez C, Cuadrado ML (2015) Safety of intra-cerebrospinal fluid chemotherapy in onco-haematological patients: a retrospective analysis of 627 interventions. *J Neurooncol* 125 (2): 351-358. doi: 10.1007/s11060-015-1922-y.
- [34] Perrin RG, Lishner M, Guha A, Curtis J, Feld R, Messner H (1990) Experience with Ommaya reservoir in 120 consecutive patients with meningeal malignancy. *Can J Neurol Sci* 17 (2): 190-192.
- [35] Peyrl A, Chocholous M, Azizi AA, Czech T, Dorfer C, Mitteregger D, Gojo J, Minichmayr E, Slave I (2014) Safety of Ommaya reservoirs in children with brain tumors: a 20-year experience with 5472 intraventricular drug administrations in 98 patients. *J Neurooncol* 120 (1): 139-145. doi: 10.1007/s11060-014-1531-1.
- [36] Pompe RS, von Bueren AO, Mynarek M, von Hoff K, Friedrich C, Kwiecien R, Treulieb W, Lindow C, Deinlein F, Fleischhack G, Kuehl J, Rutkowski S (2015) Intraventricular methotrexate as part of primary therapy for children with infant and/or metastatic medulloblastoma: Feasibility, acute toxicity and evidence for efficacy. *Eur J Cancer* 51 (17): 2634-2642. doi: 10.1016/j.ejca.2015.08.009.
- [37] Roguski M, Rughani A, Lin CT, Cushing DA, Florman JE, Wu JK (2015) Survival following Ommaya reservoir placement for neoplastic meningitis. *J Clin Neurosci* 22 (9): 1467-1472. doi: 10.1016/j.jocn.2015.04.003.
- [38] Sampath R, Wadhwa R, Tawfik T, Nanda A, Guthikonda B (2012) Stereotactic placement of ventricular catheters: does it affect proximal malfunction rates? *Stereotact Funct Neurosurg* 90 (2): 97-103. doi: 10.1159/000333831.
- [39] Sandberg DI, Bilsky MH, Souweidane MM, Bzdil J, Gutin PH (2000) Ommaya reservoirs for the treatment of leptomeningeal metastases. *Neurosurgery* 47 (1): 49-54. doi: 10.1097/00006123-200007000-00011.
- [40] Schlegel U, Pels H, Glasmacher A, Kleinschmidt R, Schmidt-Wolf I, Helmstaedter C, Fliessbach K, Deckert M, Van Roost D, Fimmers R, Bode U, Klockgether T (2001) Combined systemic and intraventricular chemotherapy in primary CNS lymphoma: a pilot study. *Journal of Neurology Neurosurgery and Psychiatry* 71 (1): 118-122. doi: 10.1136/jnnp.71.1.118.
- [41] Siegal T, Pfeffer MR, Steiner I (1988) Antibiotic therapy for infected Ommaya reservoir systems. *Neurosurgery* 22 (1 Pt 1): 97-100.
- [42] Steinherz P, Jereb B, Galicich J (1985) Therapy of CNS leukemia with intraventricular chemotherapy and low-dose neuraxis radiotherapy. *J Clin Oncol* 3 (9):1217-1226. doi: 10.1200/jco.1985.3.9.1217.
- [43] Stewart DJ, Maroun JA, Hugenholtz H, Benoit B, Girard A, Richard M, Russell N, Huebsch L, Drouin J (1987) Combined intraommaya methotrexate, cytosine arabinoside, hydrocortisone and thio-TEPA for meningeal involvement by malignancies. *J Neurooncol* 5 (4): 315-322.
- [44] Szvalb AD, Raad, II, Weinberg JS, Suki D, Mayer R, Viola GM (2014) Ommaya reservoir-related infections: Clinical manifestations and treatment outcomes. *Journal of Infection* 68 (3):.216-224. doi:10.1016/j.jinf.2013.12.002
- [45] Takahashi M, Yamada R, Tabei Y, Nakamura O, Shinoura N (2007) Navigation-guided Ommaya reservoir placement: implications for the treatment of leptomeningeal metastases. *Minim Invasive Neurosurg* 50 (6):.340-345. doi: 10.1055/s-2007-993162.
- [46] Weiner GM, Chivukula S, Chen CJ, Ding D, Engh JA, Amankulor N (2015) Ommaya reservoir with ventricular catheter placement for chemotherapy with frameless and pinless electromagnetic surgical neuronavigation. *Clinical Neurology and Neurosurgery* 130:61-66. doi: 10.1016/j.clineuro.2014.12.018.
- [47] Yoshida S, Morii K (2005) Intrathecal chemotherapy for patients with meningeal carcinomatosis. *Surg Neurol* 63 (1):52-55; discussion 55. doi: 10.1016/j.surneu.2004.06.011.
- [48] Young GA, Milliken S, Jurd J, Poulgrain P, Vincent PC (1986) The intraventricular reservoir in the treatment of neurological disease secondary to hematological malignancy: an eight year experience. *Aust N Z J Med* 16 (3): 373-377.
- [49] Zairi F, Le Rhun E, Tetard MC, Kotecki N, Assaker R (2011) Complications related to the placement of an intraventricular chemotherapy device. *J Neurooncol* 104 (1):247-252. doi: 10.1007/s11060-010-0474-4.

- [50] Zairi F, Le Rhun E, Bertrand N, Boulanger T, Taillibert S, Aboukais R, Assaker R, Chamberlain MC (2015) Complications related to the use of an intraventricular access device for the treatment of leptomeningeal metastases from solid tumor: a single centre experience in 112 patients. *Journal of Neuro-Oncology* 124 (2): 317-323. doi: 10.1007/s11060-015-1842-x.
- [51] Zhang J, Liu Z, Hou R (2014) [Treatment of multiple or recurrent intracranial tumors with local chemotherapy by hypodermic Ommaya reservoir]. *Zhonghua Yi Xue Za Zhi* 94 (3): 212-214.
- [52] Foerster MV, Pedrosa FDR, da Fonseca TCT, Couceiro TCD, Lima LC (2015) Lumbar punctures in thrombocytopenic children with cancer. *Pediatric Anesthesia* 25 (2):206-210. doi: 10.1111/pan.12527.
- [53] Gaviani P, Corsini E, Salmaggi A, Lamperti E, Botturi A, Erbetta A, Milanesi I, Legnani F, Pollo B, Silvani A (2013) Liposomal cytarabine in neoplastic meningitis from primary brain tumors: a single institutional experience. *Neurol Sci* 34 (12): 2151-2157. doi: 10.1007/s10072-013-1358-0.
- [54] Gonzalez-Barca E, Canales M, Salar A, Ferreiro-Martinez JJ, Ferrer-Bordes S, Garcia-Marco JA, Sanchez-Blanco JJ, Garcia-Frade J, Penalver J, Bello-Lopez JL, Sancho JM, Caballero D, Grp G (2016) Central nervous system prophylaxis with intrathecal liposomal cytarabine in a subset of high-risk patients with diffuse large B-cell lymphoma receiving first line systemic therapy in a prospective trial. *Annals of Hematology* 95 (6): 893-899. doi: 10.1007/s00277-016-2648-4.
- [55] Howard SC, Gajjar A, Ribeiro RC, Rivera GK, Rubnitz JE, Sandlund JT, Harrison PL, de Armendi A, Dahl GV, Pui CH (2000) Safety of lumbar puncture for children with acute lymphoblastic leukemia and thrombocytopenia. *JAMA* 284 (17): 2222-2224.
- [56] Jaeckle KA, Phuphanich S, van den Bent MJ, Aiken R, Batchelor T, Campbell T, Fulton D, Gilbert M, Heros D, Rogers L, O'Day SJ, Akerley W, Allen J, Baldas S, Gertler SZ, Greenberg HS, LaFollette S, Lesser G, Mason W, Recht L, Wong E, Chamberlain MC, Cohn A, Glantz MJ, Guthell JC, Maria B, Moots P, New P, Russell C, Shapiro W, Swinnen L, Howell SB (2001) Intrathecal treatment of neoplastic meningitis due to breast cancer with a slow-release formulation of cytarabine. *British Journal of Cancer* 84 (2):157-163. doi: 10.1054/bjoc.2000.1574.
- [57] Keidan I, Biellorei B, Berkenstadt H, Aizenkraft A, Harel R, Huna-Baron R, Kaplinsky C (2005) Prospective evaluation of clinical and laboratory effects of intrathecal chemotherapy on children with acute leukemia. *Journal of Pediatric Hematology Oncology* 27 (6):307-310. doi: 10.1097/01.mph.0000168729.32463.7b.